Multimodal Weakly Supervised Multiple Instance Learning model for Prediction of Remission Failure in Pediatric Crohn's Disease

Sooyoung Jang, MD*[1], Min Kyoon Yoo*[1], Eun Joo Lee, MD, PhD[2], Sowon Park, MD, PhD[2], Hyeji Lim, MD[2], JaeSeong Hong[1], Jong Hyun Kim, MS[3], Bo Kyu Choi, MD, PhD[1], Hong Koh, MD, PhD[2], Yu Rang Park, PhD[1]

[1]Department of Biomedical Systems Informatics, Yonsei University College of Medicine, Seoul, Republic of Korea.

[2]Division of Gastroenterology, Hepatology and Nutrition, Department of Pediatrics, Yonsei University College of Medicine, Severance Fecal Microbiota Transplantation Center, Severance Hospital, Seoul, Republic of Korea.

[3]LG AI Research, Seoul, Republic of Korea.

*Sooyoung Jang and Min Kyoon Yoo contributed equally to this research.

Background

- Crohn's disease (CD) is a chronic inflammatory bowel disease characterized by skip lesions and transmural inflammation throughout the gastrointestinal tract. CD prognosis assessment at the time of diagnosis relies on clinical parameters, endoscopic findings, and magnetic resonance enterography (MRE) imaging.
- Deep learning approaches for predicting CD remission failure remain unexplored, despite its clinical significance in disease progression. Multimodal data integration remains challenging in endoscopy and MRE analysis, as these modalities generate multiple images per patient requiring labor-intensive image-by-image labeling.

Methods

- We developed MMIL (Multimodal Multiple Instance Learning), a novel deep learning framework that integrates endoscopic images, MRE images, and clinical data using weakly supervised multiple instance learning.

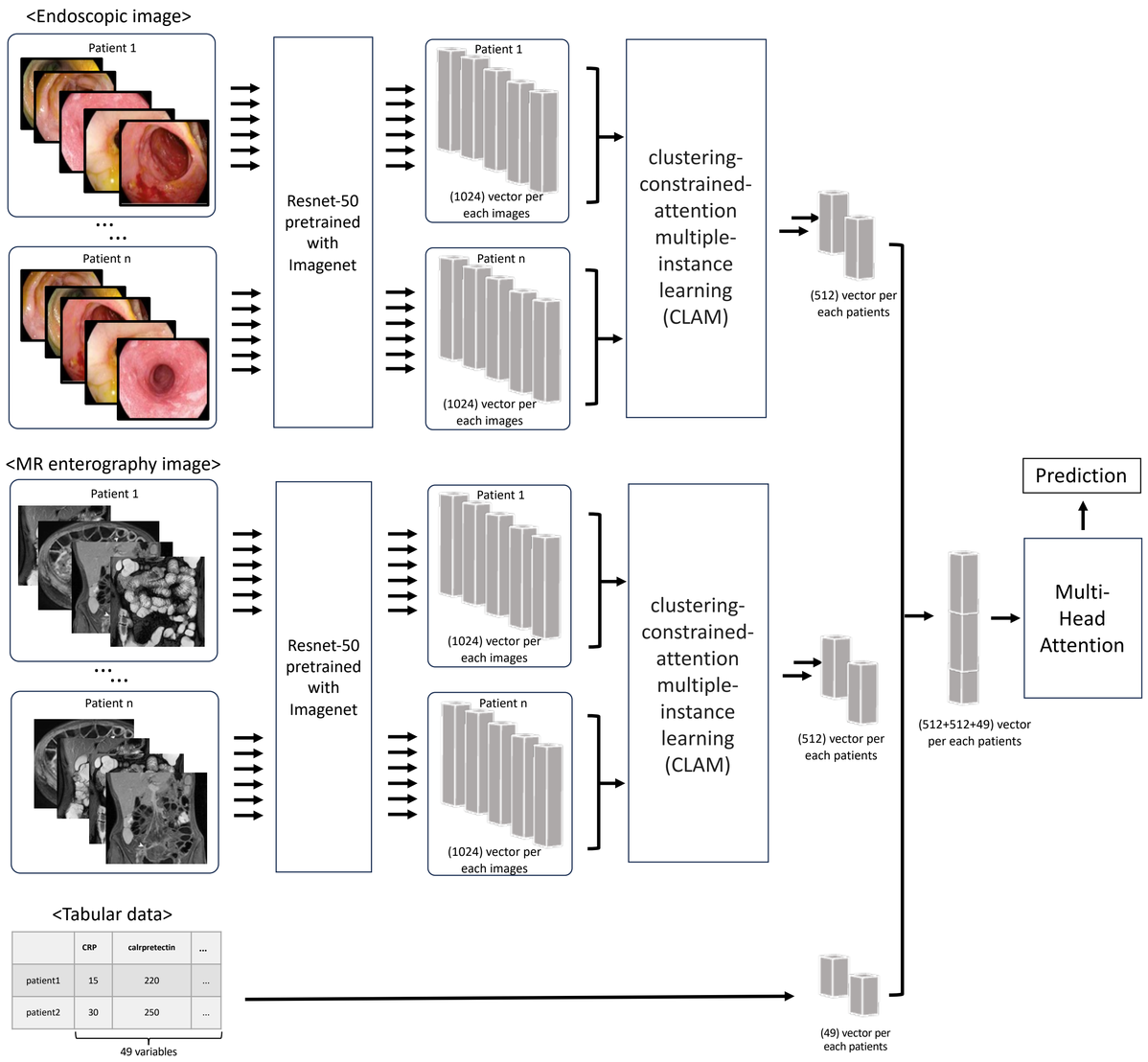

- The model implements clustering-constrained attention multiple instance learning for endoscopic and MRE images, followed by multimodal feature integration with attention-based fusion. Model evaluation was performed using 10-fold cross-validation.

Results

- We analyzed data from Severance Hospital, including 127 pediatric CD patients with 5,217 endoscopic images, 181,497 MRE images, and 49 clinical parameters.

		Overall	Remission	Remission failure
n		134	106	28
Location, n (%)	L1	28 (20.9)	24 (22.6)	4 (14.3)
	L2	3 (2.2)	2 (1.9)	1 (3.6)
	L3	103 (76.9)	80 (75.5)	23 (82.1)
L4 modifier, n (%)		18 (31.0)	15 (31.2)	3 (30.0)
Behavior, n (%)	B1	113 (84.3)	89 (84.0)	24 (85.7)
	B2	15 (11.2)	11 (10.4)	4 (14.3)
	B3	6 (4.5)	6 (5.7)	-
perianal involvement, n (%)		90 (67.2)	71 (67.0)	19 (67.9)

Results

- MWMIL demonstrated an AUROC of 0.824, exhibiting superior performance compared to unimodal approaches using XGBoost with clinical data (AUROC 0.685), CLAM with MRE images (AUROC 0.730), and CLAM with endoscopic images (AUROC 0.808). The model surpassed clinician performance across sensitivity, specificity, and accuracy metrics.

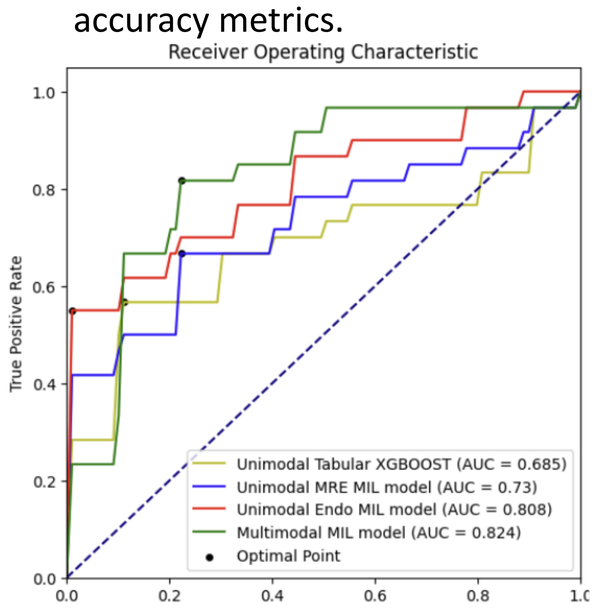

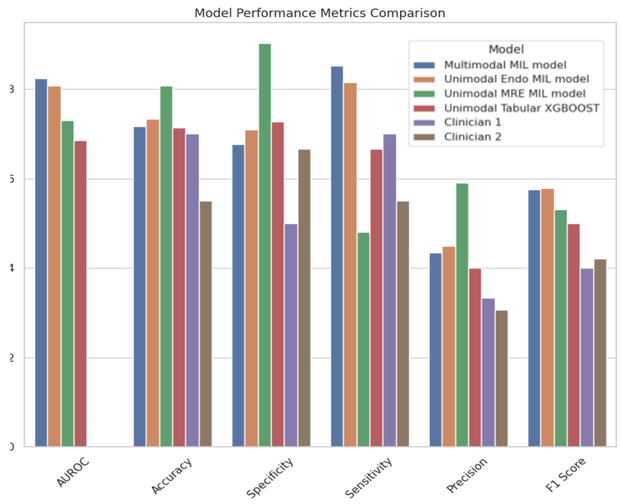

- The attention mechanism identified clinically relevant features, with severe inflammatory lesions showing high attention scores in remission failure cases.

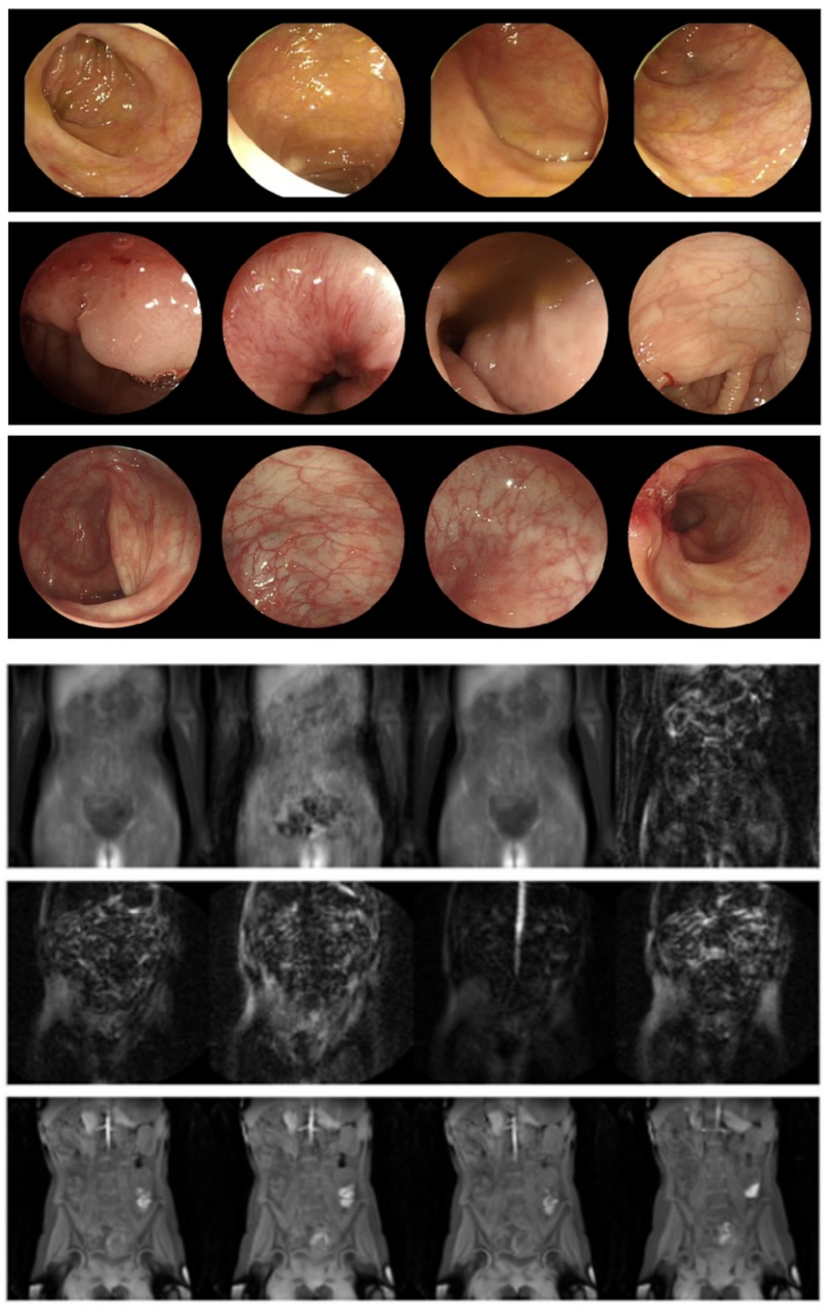

Conclusion

- This investigation establishes remission failure in CD as a distinguishable prognostic indicator at initial diagnosis.
- MMIL demonstrates the efficacy of weakly supervised multiple instance learning in analyzing complex medical imaging data without image-level annotations, advancing the framework for multimodal data integration in comprehensive clinical assessment scenarios.